
Chapter 4

Quantification Methods in Contrast Echocardiography

María J. Ledesma-Carbayo • Norberto Malpica • Andrés Santos
Miguel Angel García Fernández • Manuel Desco

Introduction

Ultrasonographic contrast agents in echocardiography are a rapidly developing research field. Several new acquisition techniques particularly suited to the acquisition of contrast images have been made available in the last few years, although the clinical usefulness of most of them is still under evaluation.

The two main goals for the use of these agents are the enhancement of the boundary between myocardial tissue and blood, and the analysis of myocardial perfusion.

The enhancement of the endocardial border observed after contrast administration [1] increases the conspicuity of the images and improves the results provided by the algorithms oriented to the assessment of ventricular wall motion. It also enables the use of more advanced semiautomatic quantitative procedures, which demand the highest image quality.

The second application mentioned is the direct assessment of myocardial blood flow

and flow reserve. Provided this assessment was clinically reliable it would play a crucial role for the determination of the functional impact of the coronary artery disease. To date, the results have been interpreted mainly visually, either qualitatively or establishing semiquantitative scores. However, the use of true quantitative techniques, based on parametric models, is of increasing interest because of its higher objectivity.

Despite the numerous advances in acquisition and postprocessing techniques attained in the past years, it is remarkable that clinical acceptance remains low. Some reasons for this reportedly slow incorporation [2] into the routine practice may be the complexity of the methodology, the difficulty of the visual interpretation of the results and the lack of standardized quantification procedures and cut-off values agreed upon for the different parameters. It is even debatable whether the quantitative values provided by the various existing software packages (supplied either by scanner manufacturers or third-party companies)

are totally equivalent. At present, many clinical studies still rely on an essentially qualitative interpretation of the images, while the most advanced mathematical approaches seem to lack sound clinical validation, confirmed by independent publications.

Acquisition of Contrast Studies

The acquisition protocol determines the quantification algorithms that can be applied to the dataset. The quantification algorithm must be suited to the contrast administration method (infusion or bolus) and to the particular imaging technique used (triggered, real-time, intermittent imaging, etc.). It is thus appropriate to briefly describe some concepts related to the acquisition protocol as far as they condition the quantitative analysis.

Contrast Administration Techniques

Bolus administration consists of a rapid injection (about 30 s) of a small amount of contrast agent, usually non-diluted. It is done through an intravascular line and is usually followed by a saline solution flush (about 5 ml) to push the bolus further into the blood stream. Direct intracoronary injection is a variant of this technique, mostly used in experimental studies.

Bolus administration saves time and is relatively easy to perform. It has been indicated for applications such as endocardial border detection and, in some cases, qualitative myocardial perfusion rest studies. Draw-

backs of this technique are the short time available to acquire the data and its lower reproducibility reported in comparative studies [2]. Quantitative measurements of timings and high-peak video density may potentially mitigate these problems (see paragraph “Bolus Analysis”).

The alternative administration technique, known as continuous infusion, is often achieved by means of a mechanical pump that performs a slow delivery of a diluted solution of the contrast agent. It offers several advantages, such as a longer period for imaging acquisition, a video intensity well within the optimum detection range, and a lower shadowing effect due to attenuation artefact. On the other hand, it is more difficult to perform and the stability of the contrast solution along the infusion becomes a critical issue, since changes in contrast concentration may affect the shape of the input function altering the quantification results. Despite these disadvantages, continuous infusion is clearly the preferred method for myocardial perfusion studies, particularly when performing quantitative analysis [3, 4].

Imaging Techniques

The last decade has been extremely productive combining contrast agent properties and imaging techniques. Initially, fundamental imaging was applied in contrast echocardiography basically after direct intracoronary injection of the agent, observing a noticeable left ventricular cavity opacification and, to some extent, myocardial changes in video intensity. The combina-

tion of fundamental imaging and Doppler echocardiography provided a better framework to improve cardiovascular flow measurements. However, harmonic imaging, in some cases combined with Doppler echocardiography, provided the greatest improvement toward a proper myocardial perfusion quantification [5, 3].

From that time, a boom of different acquisition techniques took place, taking advantage of a deeper knowledge of the interaction between microbubbles and the ultrasonic wave. When microbubbles are exposed to ultrasound pressure they change in size until they begin to resonate, even leading to a bubble disruption if the peak pressure is over 1 MPa [2]. The behavior is directly related to the peak pressure (related to the incident ultrasound transmit power), that can be controlled through the mechanical index parameter. Peak tissue pressure and its effect on microbubbles are usually measured through a parameter known as ‘mechanical index’ (MI), equal to the peak negative pressure divided by the square root of the frequency. This parameter reflects the normalized energy to which a target is exposed, usually defined at 1 MHz. Microbubbles present linear oscillations for MI below 0.1, nonlinear oscillation for MI between 0.1 and 1.0 and disruption for MI above 1.0. According to this parameter, it is customary to classify the different acquisition methods as *destructive*, those that use high MI, and *nondestructive* when low MI is applied.

Discrimination between the signal corresponding to the microbubbles from that of the tissue can be performed by exploiting

different consequences of the nonlinear behavior of the microbubbles. One approach is based on the fact that nonlinear interactions produce backscatter signals with higher power in signal harmonics. A second approach makes use of the phase shift with respect to the transmitted signal produced in the backscatter signal by the nonlinear oscillations. Most of the current acquisition methods send successive ultrasound pulse packets with different properties, either in amplitude or phase. Pulse processing consists of adding successive responses in such a way that the linear response of tissues is cancelled, selecting the nonlinear response of the contrast agent. Among these methods we can distinguish *multiple-pulse methods* and *single-pulse methods*. Multiple-pulse methods send several pulse packages for every scan line; line response is the result of the processing of these multiple pulses. Single-pulse methods combine single-pulse response of consecutive lines to cancel tissue signal. These methods, reviewed in [6], are globally called *nonlinear harmonic imaging methods* and can be used either with high or low mechanical index.

Table 4.1 summarizes some commercially available imaging techniques from those described in the previous paragraphs, indicating their most common brand name.

It may be interesting to indicate which techniques are more adequate depending on the type of quantitative assessment intended. In this sense, as indicated before, two main types of studies can be defined: those aiming at tracking the endocardial wall border and those that pursue a direct quantification of myocardial perfusion.

Table 4.1. Correspondence between major imaging methods and some commercially available techniques, indicating whether they use high or low mechanical index (MI)

| Methods | Brand names | MI |
|-----------------------------|---|----------|
| Fundamental imaging | | High |
| Harmonic imaging | Second Harmonic Imaging | High |
| | Ultraharmonic Imaging ^a | High |
| Doppler harmonic imaging | Color Power Angio ^b | High |
| | Power Harmonic Imaging ^a | High |
| | Power Doppler ^b | High |
| Single-pulse transmission | CCI ^b (Cadence Coherent Contrast Imaging) | Low/High |
| Multiple pulse transmission | CPS ^b (Cadence Contrast Pulse Sequencing Technology) | Low/High |
| | Power Modulation ^a | Low/High |
| | Coded Harmonic Agio ^c | Low/High |
| | Power Pulse Inversion ^d | Low/High |
| | Power Harmonic Imaging ^a | Low/High |

^aPhilips/Agilent; ^bSiemens Acuson; ^cGeneral Electric; ^dPhilips/ATL

Quantitative Myocardial Border Tracking

Studies to be analyzed for quantitative border tracking have been mainly acquired with bolus administration of a nondiluted contrast agent, usually acquiring one only cycle [7]. However, it has also been proposed to use continuous infusion in order to attain a more controlled environment allowing one to acquire several views [8]. Concerning imaging techniques, harmonic imaging or Doppler harmonic imaging are recommended [9, 7, 2], although other methods, such as continuous imaging with low mechanical index, have also been used to assess motion and perfusion at the same time [10].

Quantitative Myocardial Perfusion

It is impossible to establish one only acquisition technique suitable for quantitative

assessment of myocardial perfusion, since most of the imaging techniques, administration methods, and acquisition parameters have been used to this purpose, leading to the existence of multiple combinations of protocols. This fact, combined with the machine and contrast agent dependence, affects the repeatability of the results very negatively, giving rise to a certain confusion in the literature.

Harmonic imaging has been proven to be superior to fundamental imaging for myocardial perfusion [5]. Recently, nonlinear methods combining multiple pulses have been reported as the preferred methods [11]. Regarding administration techniques, both bolus and continuous infusion allow application of quantification algorithms, although usually the latter is the preferred method [3, 4, 11]. The most common acquisition protocols are the following:

1. Triggered imaging using high MI after a bolus administration. Perfusion can be quantified by applying a gamma model (see paragraph “Bolus Analysis”).
2. Continuous imaging (real-time imaging) combined with nonlinear harmonic multiple pulse cancellation methods and low mechanical index. These methods require continuous infusion. Acquisition consists of a high MI burst to disrupt most of the agent in the ventricular cavity, followed by multiple low MI pulses that allow sampling of the reperfusion process from which one or more curves are drawn that can be analyzed according to an exponential model (see paragraph “Reperfusion Model”).
3. Intermittent imaging. This acquisition protocol uses an incremental time triggering combined with nonlinear harmonic multiple pulse cancellation methods and high MI. The basis of this acquisition method is the strong, brief nonlinear echo produced when bubbles disrupt. First a prolonged high MI burst is applied to destroy all the agent present in the cavity and myocardium. Triggers are then programmed to be produced incrementally in time to obtain the refilling curve. As in the previous case, quantification of the results is also based on a reperfusion exponential model (see paragraph “Reperfusion Model”).

Contrast-Enhanced Endocardial Border Detection Quantification

The assessment of regional myocardial wall function has always been an important and

unresolved issue since the introduction of echocardiography as a diagnostic tool. Many cardiac pathologies are characterized by developing regional wall motion abnormalities, specially in early stages of the disease, in spite of well preserved indices of global performance. Abnormal regional wall motion is an early finding in many cardiac pathologies and has a critical importance in terms of an early diagnosis of the disease process.

Global and regional wall motion have been commonly qualitatively assessed by visual examination of the endocardial displacement and wall thickening of each myocardial segment. Although the American Society of Echocardiography proposed standardized protocols for acquisition and scoring of stress echocardiography [12], a significant interinstitutional disagreement on regional analysis interpretation was reported [13]. More objective quantitative methods are warranted to homogenize the interpretation of these studies.

The automated assessment of cardiac motion has been intensively pursued in the last decade [14]. Lately, most of the efforts are being made in cardiac magnetic resonance imaging, and more specifically in tagged magnetic resonance, which are currently the reference modalities to estimate cardiac motion [15]. While new ultrasound techniques provide higher image quality, increasing attention is being paid to the automatic processing of echocardiographic sequences [16-18].

An automatic tracking of the endocardial border may allow for a more objective evaluation of stress echocardiography and an easier calculation of global function param-

eters, such as ventricular volume and ejection fraction. These automatic algorithms may clearly benefit from contrast echocardiography, as it noticeably enhances the tissue–blood interface, [1, 19], particularly when combined with the new nonlinear harmonic acquisition technique. It is currently recommended for clinical use in global functional examination and stress echocardiography when conventional ultrasound imaging is suboptimal [7].

The simplest approach for quantitative left ventricular global function assessment based on border tracking uses a manual contour delineation in systolic and diastolic frames, allowing computation of ejection fraction-related parameters. The use of contrast agents may allow for the use of semi-automatic thresholding techniques to define the endocardial border [10].

Contrast echocardiography may also allow

one to extend the conventional color kinesis to a broader group of patients, providing a very good visualization together with a quantification of the endocardial excursion magnitude and timing [20].

The technique known as ‘acoustic quantification’ (AQ, Philips-Agilent) produces a rough segmentation of cardiac structures by thresholding the backscatter signal from conventional ultrasound studies. Slight changes in AQ configuration allow its use for the quantification of contrast studies [21] providing a more reliable automatic endocardial delineation.

More advanced image processing methods are based on mathematical tools known as ‘active’ or ‘deformable’ models. These models, which can be used to generate a completely automatic segmentation of the sequences, consist in geometrical curves that evolve toward the image edges. The algo-

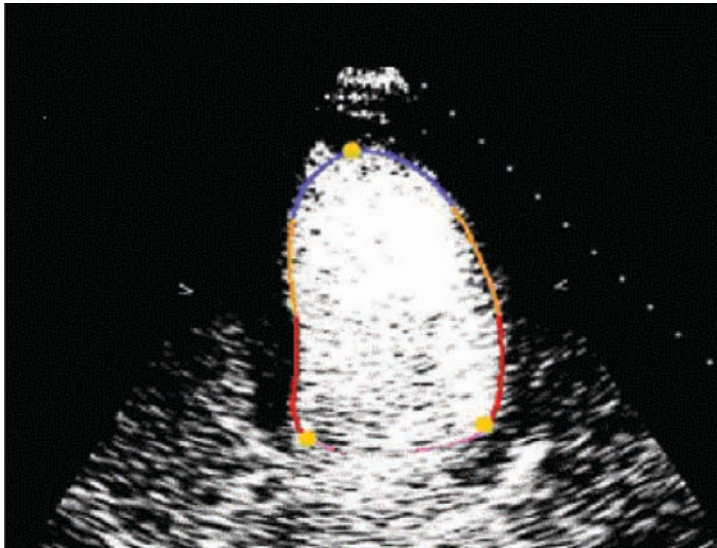


Fig. 4.1. Tracking of endocardial border in contrast-enhanced two-dimensional sequences. The tracked contour is presented as a color overlay

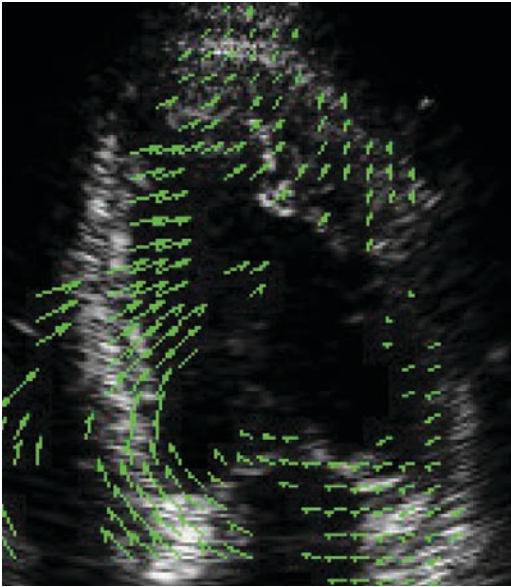


Fig. 4.2. Dense myocardial displacement field in a patient with hypokinetic function of the lateral wall and the basal and distal septum segments

rithms operate iteratively, changing the shape and dimensions of the borders until converging to the real structure edges. Prior constraints can be added to adapt the deformable model to a particular shape [17]. The contours obtained after tracking the whole sequence can be processed to generate global functional parameters and regional endocardial excursion (Fig. 4.1). These methods can be extended to three-dimensional imaging (3D+T) to obtain global three-dimensional measurements [22].

Another approach is to track all the image pixels, providing a dense myocardial displacement field that represents the magnitude and direction of the movement for every pixel in the image [18]. Although this method has only been tested in noncontrast harmonic imaging for wall motion assess-

ment, it also has clear potential applications in contrast echocardiography (Fig. 4.2)¹.

This type of method may provide not only an assessment of the heart motion but also the possibility to compensate that movement, producing artificially still sequences, much more appropriate for obtaining functional information with contrast echocardiography. This issue is further detailed (see paragraph “Effect on the Cardiac Motion”).

Contrast Quantification for Myocardial Perfusion Assessment

A reliable assessment of the myocardial perfusion is one of the most ambitious goals of contrast echocardiography. Nevertheless, it is quite evident that, as in other imaging techniques such as nuclear medicine or cardio MRI (magnetic resonance imaging), the simple visualization of differences in video intensity between cardiac segments is not enough to provide objective, reliable and repeatable measurements.

Under some reasonable assumptions, quantitative measurements of video intensity are related to the contrast agent concentration in different myocardial regions. Thus, the video intensity information in contrast studies may be used to obtain a spatial assessment of myocardial perfusion, applying adequate models and quantification algorithms.

Myocardial perfusion assessment by means of contrast agents does not provide a high

¹ Studies in figures 2 to 10 have been processed with the CUSQ[®] software package, developed by the authors and distributed by SIEMENS-ACUSON.

spatial resolution, limiting the sensitivity in cases of small defects. However, several studies support that a good quantitative assessment improves the accuracy, even to a degree comparable to that of SPECT studies [11].

Basic Quantification

The most simple approach to contrast echocardiography quantification consists of taking video intensity measurements on regions of interest (ROI) defined in single frames or image sequences (cineloops).

Single-Frame Quantification

Once a suitable image in a sequence has been selected, the video intensity in different points or regions in the myocardium can be measured. Typically, a region-of-interest (ROI) is defined and the maximum and/or mean intensity of the pixels within the ROI is computed. ROIs could be placed within a single segment or perfusion territory. The advantage of working with ROIs instead of individual pixels is that the averaging minimizes the effect of the noise (statistical error, scatter, artifacts).

As the change in signal strength due to the contrast is usually small, its detection is hindered by the noise; the application of subtraction techniques may increase the signal-to-noise ratio. Subtraction assumes that the acquired signal is composed of the addition of signal caused by the contrast agent and 'background' information or noise. If this second component is identified, it can be subtracted. This is usually achieved by

acquiring several images before the contrast appearance and subtracting the average value of these images. Obviously, it is necessary to acquire all the images at the same moment in the cardiac cycle, or alignment methods have to be applied (see paragraph "Effect on the Cardiac Motion").

It is also possible to define linear ROIs or 'profiles' and to draw a graph of intensities along the line. In this way, spatial variations of intensity (variations of perfusion) along the line can be easily visualized. These profiles do not have to be straight lines, since the user can define any curve as desired (Fig. 4.3).

Single-frame quantification provides a way of determining relative perfusion values between different myocardial regions, although it is an oversimplistic method that cannot deal with movement or time evolution information. When this information is required, sequences or cineloops of images have to be analyzed.

Sequence Quantification

The interpretation of image intensity data as a function of time provides functional information of clinical relevance. A sequence or cineloop of images can be analyzed by obtaining a time curve of the evolution of video intensity in different ROIs or in every pixel. Usually, mean intensity within the ROI, after background subtraction, is displayed as a function of time. ROIs are defined as in single-image analysis, but in this case, their position in the myocardium should be corrected along the sequence (see paragraph "Effect on the Cardiac Motion" for automatic or semiautomatic ROI repositioning) (Fig. 4.4).

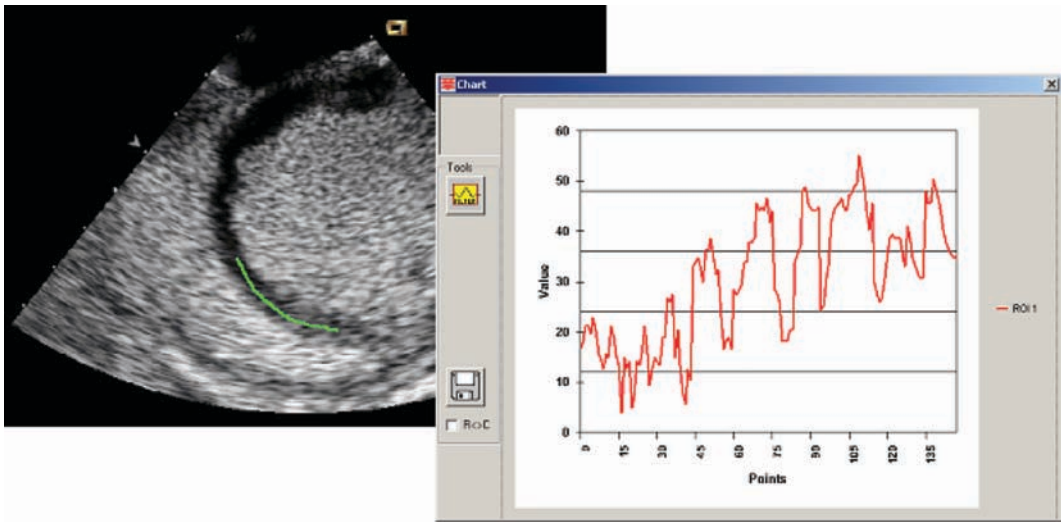


Fig. 4.3. Video intensity along a profile drawn within the myocardium

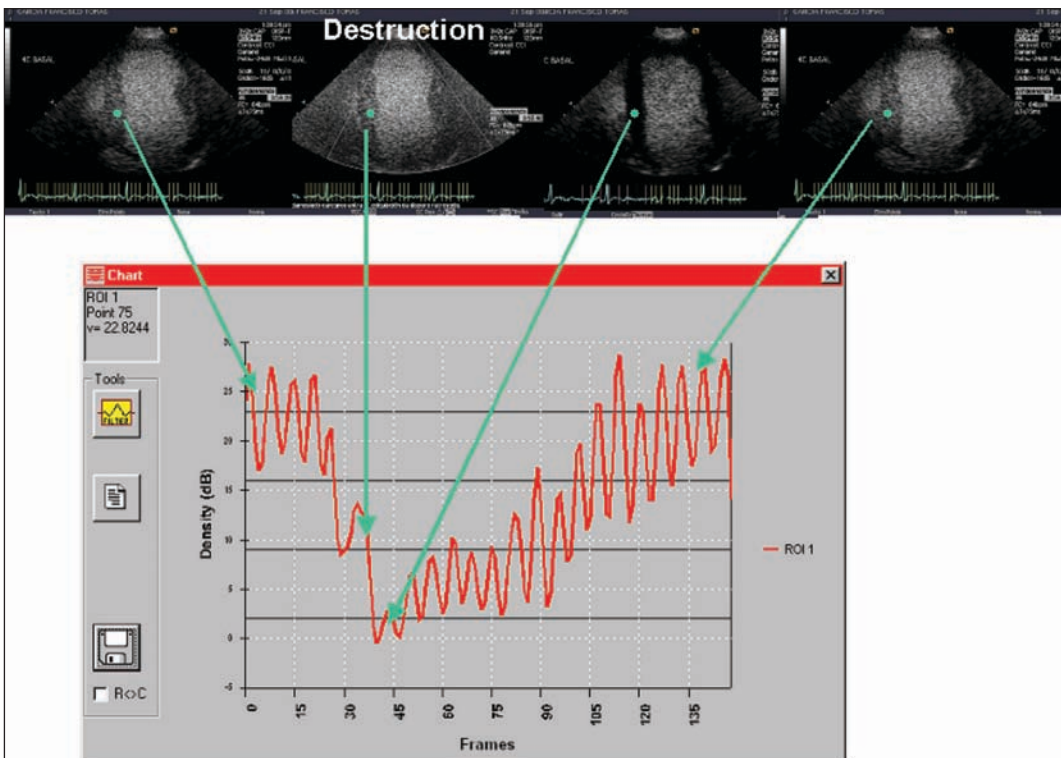


Fig. 4.4. Evolution of the video intensity along time in a ROI drawn within the myocardium. The *second frame* corresponds to the moment when a high MI burst is applied. From that moment on, reperfusion of the myocardial tissue takes place and can be quantified applying a proper mathematical model

Another way of visualizing spatial and temporal information together is the creation of a curved or calculated M-mode: a line is defined within the myocardium and the video intensity for each point in the curve at successive frames is depicted in an M-mode-like image (Fig. 4.5).

Parametric Quantification

Microbubbles, unlike most of the nuclear medicine tracers used for myocardial perfusion imaging, can be considered strictly intravascular, as they remain in the intravascular space during their transit through the myocardium [2]. For this reason, quantitative information about myocardial blood flow and/or myocardial blood volume can be obtained by applying well-known math-

ematical models derived from indicator dilution principles [23].

Two main models are applicable, depending on whether the administration of the contrast agent was performed with bolus injection or continuous infusion.

Bolus Analysis

Visual analysis of the video intensity variations after a bolus injection is difficult and cannot provide objective parameters. Quantitative analysis to obtain information related to the blood flow in the myocardium can be performed applying classical mathematical methods.

For this kind of analysis, end-systolic images are acquired from each cardiac cycle from just before contrast injection until its disappearance [3]. Prior to the contrast

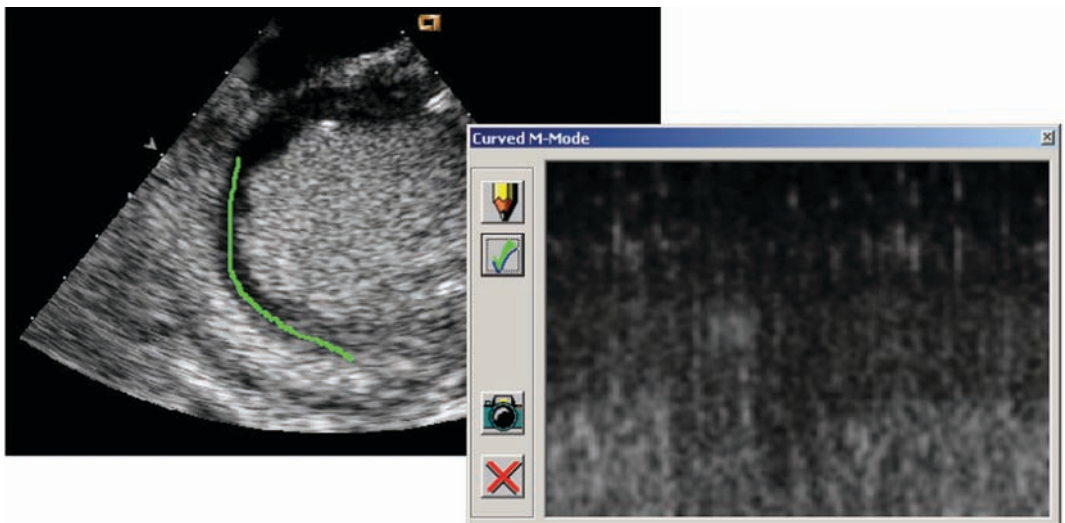


Fig. 4.5. Curved M-mode. A curve is drawn in a frame and exported to all the remaining frames of the sequence (allowing repositioning). The calculated M-mode image visually represents the changes in video intensity along time

appearance, four to six images are acquired and averaged for background subtraction [24]. Time intensity plots from background-subtracted video intensity are then fitted to a gamma-variate function [3, 25]:

$$y = A t e^{-\alpha t} \quad (1)$$

where A is a scaling factor, t is time and α is a parameter related to the transit rate of the tracer (Fig. 4.6).

From this model, the following parameters can be obtained:

- Peak video intensity ($A/\alpha e$), proportional to the volumetric flow.
- Time-to-peak, $1/\alpha$, time from the beginning of the curve to the maximum intensity.
- Mean transit time (MTT) of the bolus, the average time that the contrast agent takes to travel through the volume under analysis. It corresponds to the center of

gravity of the curve, which only coincides with the time of the maximum in symmetrical curves. It is calculated as the first moment of the concentration time intensity plot, approximately equal to $2/\alpha$. (Fig. 4.6).

The mean transit rate (reciprocal of MTT) of a tracer through a sample of myocardial tissue is proportional to the flow-to-volume ratio. Its changes, thus, reflect changes in the regional blood flow if the coronary blood volume is constant or the variations in blood volume if the flow is constant.

The accuracy of the relation between the MTT parameter and myocardial flow has been validated in experimental models and clinical perfusion studies. For example, Wei et al. [3] present a comparison with radio-labeled microsphere myocardial blood flow measurements, showing that a mild to mod-

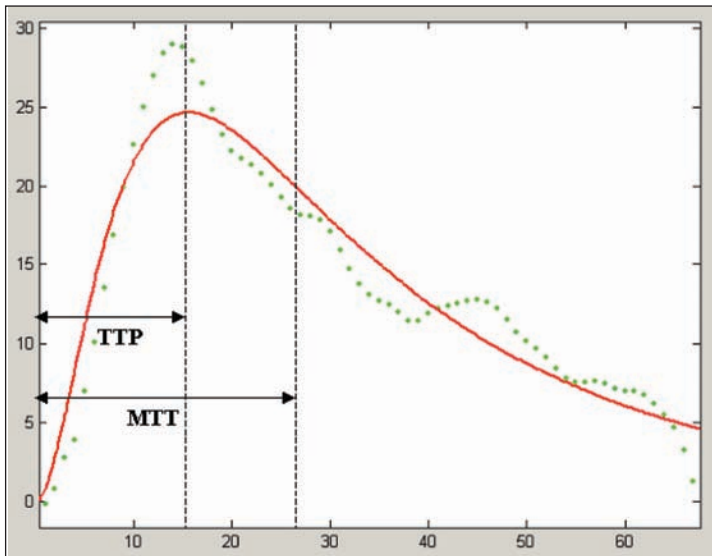


Fig. 4.6. Gamma-variate function (red) fitted to a real perfusion curve (green dots). Time-to-peak and mean transit time parameters are represented

erate stenosis (<85% lumen diameter narrowing) on an epicardial coronary artery can be detected by identifying the decrease in myocardial blood volume distal to the stenosis.

The gamma-variate function presumes that the system behaves like a two-compartment model and that the bolus entering the myocardial bed is perfect, in the sense of following a mathematical delta function (infinitely short). The lack of detailed knowledge about the shape of the input function, among other technical difficulties, limits the accuracy and usefulness of this technique in clinical practice. Other more complex models able to take into account an imperfect input function have been tested, although their accuracy has not shown to be significantly superior to that of the gamma model [3]. Continuous infusion using reperfusion models is an alternative that offers several advantages, as will be discussed in the next section.

Reperfusion Model

As seen in paragraph “Imaging Techniques”, microbubbles react in different ways to the ultrasonic pulses depending on the mechanical index. This property of the microbubble behavior can be used to measure blood reperfusion in the myocardium. A burst of high-MI pulses sent during a continuous infusion of the contrast agent destroys all the microbubbles, allowing one to record the replenishment of the myocardial tissue [26] as blood with fresh contrast agent re-enters the cardiac wall. Two different acquisition techniques are being used to study

reperfusion: continuous (real-time) imaging and intermittent imaging.

Images can be acquired in two different ways: (a) triggered mode, in which one only image per cycle is acquired, generally at end-diastole, and (b) continuous or real-time mode, in which images are acquired continuously at a relatively high frame rate. Continuous or real-time imaging makes use of a high-energy (high MI) ultrasound pulse that destroys all the microbubbles and then acquires continuously images using low MI pulses that do not destroy the microbubbles. This allows the increasing degree of myocardial reperfusion to be recorded as an increase of opacification or video intensity.

The mathematical analysis of the data is based on a single-compartment model with an input considered as a step function [25]. The model is defined by a differential equation $dC(t)/dt = \beta[G(t) - C(t)]$, which describes the change in myocardial concentration $C(t)$ within a mixing chamber of volume V with a flow-to volume ratio β , with a certain input function $G(t)$. Solving the equation when the input is a step function leads to an exponential solution of the following form:

$$y = A(1 - e^{-\beta t})$$

where y is the videointensity value, β is the video intensity increase rate, and A is the asymptotic value of video intensity after complete replenishment (value of the plateau) (Fig. 4.7). The slope at the origin ($t = 0$) is $A\beta$. It can be shown [26] that, according to the model, the blood flow (f) must be proportional to $A\beta$.

A different acquisition technique known as ‘intermittent imaging’ has also been used

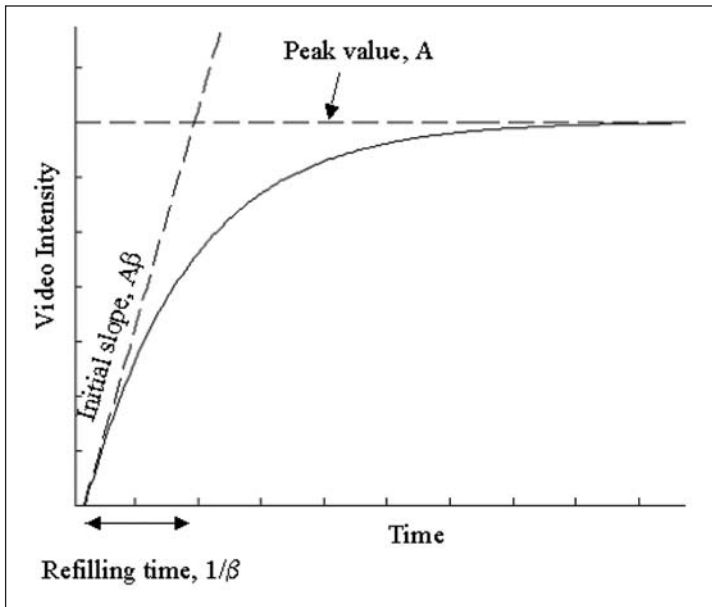


Fig. 4.7. Exponential model with parameters A , β and $A\beta$ indicated

for reperfusion assessment. With this technique, every image is acquired by using high-MI ultrasonic pulses, thus destroying all the microbubbles every time. To measure reperfusion, the time interval between pulses (pulsing interval, PI) is increased in each acquisition to allow a higher amount of contrast to reenter the field at each repetition. Wei et al. [26] proposed a two-piece linear model for the resulting curve: a linear increase in intensity until reaching a constant plateau. However, the video intensity versus pulsing interval curve is adjusted to a similar exponential model as in the previous case. The justification for this is that nonuniformities in the ultrasound beam shape and bubble destruction lead to a more 'rounded' curve that can be heuristically approximated by an exponential. An alternative reason to fit an exponential

curve may simply be to accept the same compartmental model as in the previous case, since intermittent imaging could be considered a particular case of the continuous curve, sampled at a lower (and perhaps irregular) rate.

In the case of continuous imaging, a cyclic variation of signal intensity can be observed, due to heart beating. This high-frequency variation has been analyzed in some reports, although systolic/diastolic ratios do not seem to be related to regional functional parameters [27, 28]. For this reason, to obtain a correct fitting when using real-time imaging, it is very convenient to perform a previous filtering of the curve.

The quantification procedure involves the same steps in both acquisition modes:

1. Acquisition of frames following bubble destruction.

- Regions of interest are placed within the myocardium and repositioned along the sequence, either manually or using some automatic procedure.
- Time curves are obtained for each region.
- The curves are low-pass filtered, particularly in the case of real-time acquisition.
- The parameters of the model are obtained after adjusting the curve to an exponential function by any of the mathematical algorithms available.

Figure 4.8 shows an image of a sequence with two ROIs defined. On the right, the time curves corresponding to the regions are displayed, showing the fitted exponential models. Notice the different degrees of reperfusion (values of A) and replenishment rates (described by β) corresponding to regions with normal and reduced perfusion.

Masugata et al. [29] studied the values of

the reperfusion parameters under graded coronary stenosis, and showed that β and $A\beta$ correlated well with the degree of stenosis, while A alone did not.

A comparison between real-time and intermittent triggered imaging for the quantification of coronary stenosis and transmural perfusion gradient was reported by Masugata et al. [30] using an open-chest model in dogs. They showed that both methods are equivalent, both visually and quantitatively, for the quantification of altered myocardial blood flow. With both imaging modalities, the product of $A\beta$ shows a good correlation with myocardial blood flow measured with fluorescent microspheres, higher than that of using parameters A or β alone. The asymptotic plateau of video intensity was found to be lower with real-time imaging, requiring a higher amount of

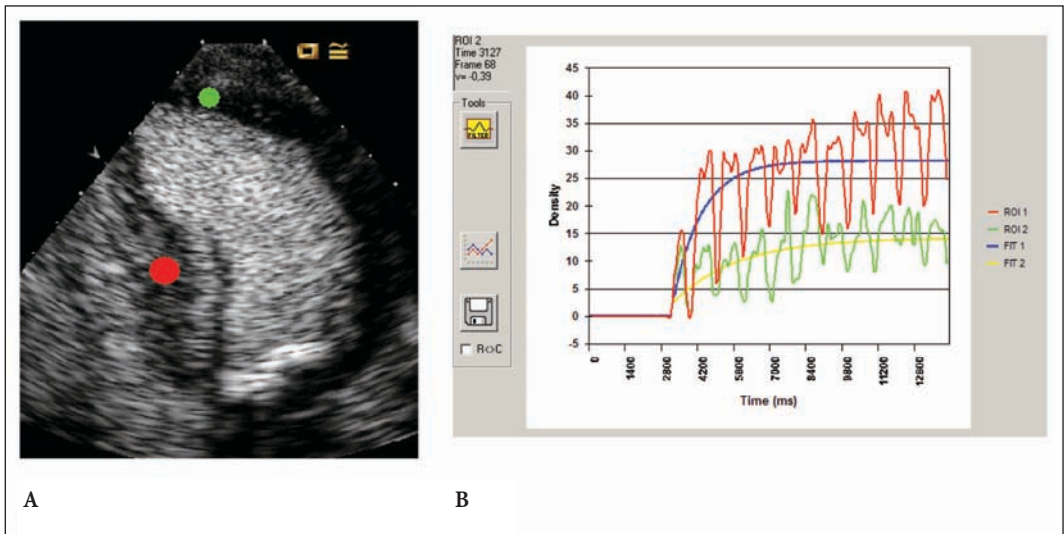


Fig. 4.8. A Two regions of interest in different myocardial segments (real-time acquisition) B Corresponding time intensity curves and fitted exponential models for both ROIs. The *green* ROI corresponds to a hypoperfused segment

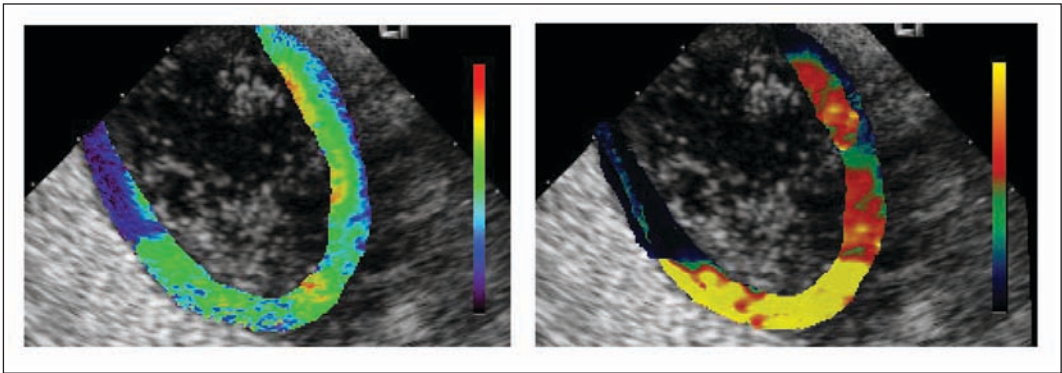


Fig. 4.9. Parametric images obtained from a mini-pig (open-chest experimental model) with reduction of the LAD coronary artery flow. Sequence was acquired with continuous infusion and real-time ECG-gated acquisition mode (CCI, Siemens-Acuson) and quantified according to an exponential model. Parameters A (left) and β (right) are overlaid in color over the first image after bubble destruction. Ischemic region shows significantly smaller A and β in comparison with the normally perfused segments

contrast to obtain the same intensity values.

A new and more attractive way of presenting these data ('parametric imaging') is being progressively introduced. It consists in obtaining time curves for all the pixels in the image instead of working only with a few number of separate ROIs [31]. Parameters of any model (A , β , $A\beta$, time to peak) can then be computed for any pixel showing their value as a color overlay in the parametric image, as shown in Fig. 4.9. Parametric imaging requires a very good alignment of all the images in the sequence (see paragraph "Effect of the Cardiac Motion").

Limitations of the Quantification Methods

Accuracy of the quantification methods as a myocardial perfusion assessment tool is impaired by several factors, whose knowledge is critical to improving reliability in

the future. Some of them may apply to all quantification techniques, while others are only relevant for model-based methods.

One problem common to all the techniques is the possible lack of linearity between video intensity and the concentration of the contrast agent. Although all the quantification techniques assume a linear relationship between regional video intensity and the concentration of the contrast agent, this is just an approximation, not fully justified in most imaging systems [23]. Two different processes are involved in this assumption: the nature of the backscatter signal depending on the microbubble concentration and the representation of this received signal as an image. Relative changes in contrast agent concentration produce variations of the ultrasound backscatter signal, also affected by scattering and absorption mechanisms during its propagation. The effect of these problems is less important when the concentration of

contrast is low, appearing as a strongly nonlinear saturation effect at higher concentrations [25]. In the sonographer, the representation of the received signal as an image is generated through a look-up table (LUT) that maps signal intensity onto video intensity (either gray level or color); this map may be (and frequently is) strongly nonlinear. To achieve a better dynamic range it is common to present the results on a scale in decibels that implies a logarithmic translation. This cause of nonlinearity is not supposed to be a problem for the quantitative analysis as it can be mathematically corrected if the look-up table is known.

Another factor that affects all the quantification methods is that intensity values may differ greatly among subjects or even among repetitions of the experiment, as a consequence of the depth-dependent attenuation of reflected sound waves. This is generally overcome by using relative measurements obtained by normalizing the video intensity of the myocardium with respect to that of the cavity.

Methods based on the reperfusion parametric quantification model have some specific limitations that may degrade the goodness-of-fit to the theoretical exponential curve:

a. Uncertainty about the position of the initial point. The initial point for curve fitting should be selected in a moment with minimum contrast. However, depending on the specific sonographer and acquisition parameter settings, a different degree of microbubble destruction is achieved [26]. Noise in this initial part of the curve can

make the resulting fit very dependent on the particular initial point chosen. Another possibility is to add a constant term (y_0) to the exponential model, to account for this nonzero initial value, obtaining the following model:

$$y = A(1 - e^{-\beta t}) + y_0$$

Other authors [31] make use of a pre-contrast image that is subtracted from all the remaining images acquired during reperfusion. This method, however, assumes a correct realignment of all frames with the precontrast image.

- b. Curve filtering. The time curve is usually low-pass filtered before adjustment to the exponential model. The type and degree of filtering can affect the adjustment and modify the value of the parameters obtained from the model.
- c. Validity of the exponential model. Throughout the quantification process it is assumed that the reperfusion process is accurately modeled by an exponential function. This is only an approximation, and the reliability of the parameters obtained is obviously limited by the goodness-of-fit of the model to the real reperfusion process. The behavior of the contrast agent during its passage through the myocardium is more complex than the model presumes. The microbubbles do not seem to pass unimpeded through the microcirculation and hence their behavior does not follow a straight compartmental model [25].

All these limitations may introduce inaccuracies in the actual values of the parameters, as obtained after the exponential fitting. The problem is particularly severe

when trying to compare values obtained with different acquisition settings or using different quantification software packages. It is, however, less worrying in comparative studies carried out with the same setting.

Finally, another source of error also common to all the quantification techniques is that due to the movement of the transducer, respiration, etc., there may be a displacement of the images along the sequence. This is especially severe when using real-time acquisition, as the position of the structures changes continuously along the heart cycle. This particularly difficult problem is addressed in the next section.

Effect of the Cardiac Motion

As already mentioned in this chapter, in most of the applications of myocardial contrast quantification, heart motion constitutes a significant source of error which needs to be corrected. The complete sequence of images or at least the ROIs must be carefully aligned to obtain accurate time curves for model fitting or to create parametric images representing a certain feature for every pixel. If it is done manually (usually with ROIs), the operator must revise the whole cine loop to validate that the position of the ROI is correct in every frame. For some applications, the only concern is that the region does not include at any moment bright values from the neighboring cavities [32]. In studies aiming at the detection of small perfusion defects or when slight differences are expected, a finer alignment must be carried out. This is the case, for example, in studies that try to calculate

endocardial/epicardial perfusion ratios [30].

Although most studies still rely on a manual alignment to properly position the ROIs [33], an increasing number of attempts of using automatic alignment or tracking tools is being observed. These automatic methods can be divided into two main groups, those using algorithms to reposition individual ROIs and registration-based approaches, in which the whole images are realigned.

Algorithms in the first group track local intensity in a pixel-to-pixel (or small neighborhoods) basis, seeking for correspondences between local gray level patterns. Among these techniques, reviewed in [34], the most representative are 'optical flow' and 'block matching' methods. Some global smoothness constraint is normally added to impose spatial coherence in the displacement field, to avoid big changes in the displacement amplitude and direction in a small neighborhood. These methods have long been proposed in conventional echocardiography as an alternative to Doppler imaging to estimate tissue motion [35] or to assess myocardial deformation [36]. We have evaluated several local block matching algorithms as a tool to track a ROI along the sequence in contrast echocardiography. Results have proven accurate enough for clinical purposes and computation times may allow for real-time processing (Fig. 4.10).

The second approach retrieves the displacement vectors for every point in the image finding the deformation field between every pair of images, in a process commonly denoted as alignment or registration. These

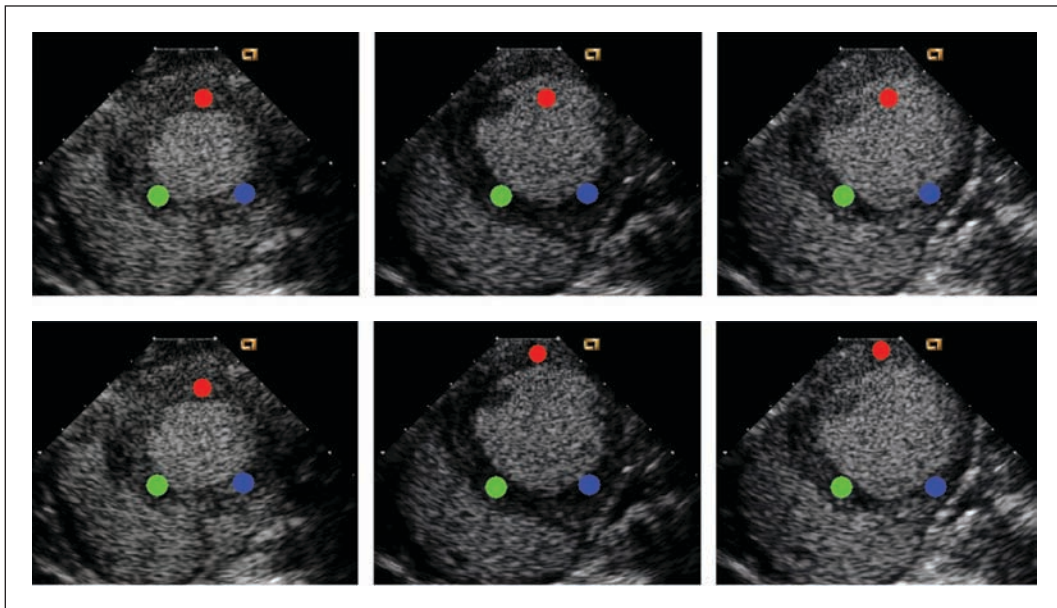


Fig. 4.10. Three frames of a sequence on which three ROIs have been defined. *Upper row* shows the position of the ROIs without any tracking. *Lower row* shows the position after automatic tracking

methods take into account all the pixels in the image (or the object of interest) in a global manner, obtaining all the displacements at the same time. The smoothness and spatial coherence is therefore automatically imposed within the deformation definition.

The deformation computed for any pair of images provides an incremental displacement between them, obtained by minimizing the difference in intensity between the two images while iteratively adjusting the deformation parameters. The intensity similarity measurements more commonly used are cross-correlation or least-squares differences. The alignment process is repeated for all the consecutive pairs of images in the cardiac cycle sequence and the incremental displacements are added together to compute the accumulated displacement

for every point in the image. Once known, the deformation field can be applied either to compute trajectories (or derived parameters: velocity, acceleration, strain, etc.) or to actually deform the images making them match each other [18, 24, 37]. The nature of the deformation depends on the acquisition technique; with triggered methods, normally rigid transformations (translation and rotation) are enough. This is the approach used in [24]. With real-time methods, nonrigid transformations are needed due to the elastic nature of the myocardium [18, 37].

An advantage of whole-image registration is that once the complete sequence is correctly aligned, all the pixels can be studied, enabling the calculation of parametric images.

Future Trends

Myocardial contrast echocardiography has evolved from the initial experiments using intra-arterial injections and fundamental imaging to a more productive environment, employing intravenous administration, more advanced acquisition techniques that enhance noticeably the image, and a quantitative interpretation of the results. The possibility of generating parametric images, that leads to results more similar to those classically obtained by other image modalities, such as nuclear medicine or cardio MRI is remarkable. However, a reliable use of parametric imaging requires a solution to the problem of movement. As mentioned in this chapter, some mathematical approaches to this issue are yielding very promising results, although clinical validation will require some more time. Nevertheless, we must take into account that these movement-correction techniques are only an approximation, since the movement of the heart takes place in 3D while the correction works strictly in-plane. Only a 3D acquisition would provide a complete dataset that would allow for an exact compensation of the displacement of the structures under

analysis. The feasibility of perfusion analysis using 3D echocardiography is stressed in some recent studies [38]. One of the problems of working in 3D is the difficult visualization of the data; Yao et al.[39] proposed a bull's-eye view to present perfusion defects. Three-dimensional echocardiography technology is not yet mature, although great advances both in acquisition and in quantification methods are expected in the near future.

Another interesting approach would be to integrate the information provided by different methods of analysis, particularly myocardial perfusion assessment and wall motion analysis. This could increase the sensitivity and specificity of myocardial contrast echocardiography.

Finally, it should be underlined that the difficult introduction of these techniques into routine practice depends mainly on the lack of standardized procedures, both for the acquisition and for the quantitative analysis. If manufacturers and users reached an accord on at least some well-tested procedures, it would be easier to collect multi-centre data to establish clinical indications and sensitivity and specificity in different pathologies and clinical situations.

References

1. Cohen JL, Cheirif J, Segar DS, Gillam LD, Gottdiener JS, Hausnerova E, Bruns DE (1998) Improved left ventricular endocardial border delineation and opacification with OPTISON (FS069), a new echocardiographic contrast agent. Results of a phase III Multicenter Trial. *J Am Coll Cardiol* 32:746-752
2. Becher H, Burns P (2000) *Handbook of Contrast Echocardiography*. Springer
3. Wei K, Jayaweera AR, Firoozan S, Linka A, Skyba DM, Kaul S (1998) Basis for detection of stenosis using venous administration of microbubbles during myocardial contrast echocardiography: bolus or continuous infusion? *J Am Coll Cardiol* 32:252-260
4. Lindner JR, Villanueva FS, Dent JM, Wei K, Sklenar J, Kaul S (2000) Assessment of resting perfusion with myocardial contrast echocardiography: theoretical and practical considerations. *Am Heart J* 139:231-240

5. Marwick TH, Brunken R, Meland N, Brochet E, Baer FM, Binder T, Flachskampf F, Kamp O, Nienaber C, Nihoyannopoulos P, Pierard L, Vanoverschelde JL, van der Wouw P, Lindvall K (1998) Accuracy and feasibility of contrast echocardiography for detection of perfusion defects in routine practice: comparison with wall motion and technetium-99m sestamibi single-photon emission computed tomography. The Nycomed NC100100 Investigators. *J Am Coll Cardiol* 32:1260-1269
6. Vannan MA, Kuersten B (2000) Imaging techniques for myocardial contrast echocardiography. *Eur J Echocardiogr* 1:224-226
7. Mulvagh SL, DeMaria AN, Feinstein SB, Burns PN, Kaul S, Miller JG, Monaghan M, Porter TR, Shaw LJ, Villanueva FS (2000) Contrast echocardiography: current and future applications. *J Am Soc Echocardiogr* 13:331-342
8. Weissman NJ, Cohen MC, Hack TC, Gillam LD, Cohen JL, Kitzman DW (2000) Infusion versus bolus contrast echocardiography: a multicenter, open-label, crossover trial. *Am Heart J* 139:399-404
9. Rubin DN, Yazbek N, Garcia MJ, Stewart WJ, Thomas JD (2000) Qualitative and quantitative effects of harmonic echocardiographic imaging on endocardial edge definition and side-lobe artifacts. *J Am Soc Echocardiogr* 13:1012-1018
10. Mor-Avi V, Caiani EG, Collins KA, Korcarz CE, Bednarz JE, Lang RM (2001) Combined assessment of myocardial perfusion and regional left ventricular function by analysis of contrast-enhanced power modulation images. *Circulation* 104:352-357
11. von Bibra H, Bone D, Niklasson U, Eurenus L, Hansen A (2002) Myocardial contrast echocardiography yields best accuracy using quantitative analysis of digital data from pulse inversion technique: comparison with second harmonic imaging and harmonic power Doppler during simultaneous dipyridamole stress SPECT studies. *Eur J Echocardiogr* 3:271-282
12. Schiller NB, Shah PM, Crawford M, DeMaria A, Devereux R, Feigenbaum H, Gutgesell H, Reichek N, Sahn D, Schnittger I, et al. (1989) Recommendations for quantitation of the left ventricle by two-dimensional echocardiography. American Society of Echocardiography Committee on Standards, Subcommittee on Quantitation of Two-Dimensional Echocardiograms. *J Am Soc Echocardiogr* 2:358-367
13. Hoffmann R, Lethen H, Marwick T, Arnese M, Fioretti P, Pingitore A, Picano E, Buck T, Erbel R, Flachskampf FA, Hanrath P (1996) Analysis of interinstitutional observer agreement in interpretation of dobutamine stress echocardiograms. *J Am Coll Cardiol* 27:330-336
14. Fedele F, Trambaiolo P, Magni G, De Castro S, Cacciotti L (1998) New modalities of regional and global left ventricular function analysis: state of the art. *Am J Cardiol* 81:49G-57G.
15. Clarysse P, Han M, Croisille P, Magnin IE (2002) Exploratory analysis of the spatio-temporal deformation of the myocardium during systole from tagged MRI. *IEEE Trans Biomed Eng* 49:1328-1339
16. Marwick TH (2002) Quantitative techniques for stress echocardiography: dream or reality? *Eur J Echocardiogr* 3:171-176
17. Jacob G, Noble JA, Kelion AD, Banning AP (2001) Quantitative regional analysis of myocardial wall motion. *Ultrasound Med Biol* 27:773-784
18. Ledesma-Carbayo MJ, Kybic J, Desco M, Santos A, Unser M (2001) Cardiac motion analysis from ultrasound sequences using non-rigid registration. In: Niessen WJ, Viergever MA (eds) MICCAI. Springer Verlag, Berlin, pp 889-896
19. Crouse LJ, Cheirif J, Hanly DE, Kisslo JA, Labovitz AJ, Raichlen JS, Schutz RW, Shah PM, Smith MD (1993) Opacification and border delineation improvement in patients with suboptimal endocardial border definition in routine echocardiography: results of the Phase III Alburnex Multicenter Trial. *J Am Coll Cardiol* 22:1494-1500
20. Takeuchi M, Yoshitani H, Miyazaki C, Haruki N, Otani S, Sakamoto K, Yoshikawa J (2003) Color kinesis during contrast-enhanced dobutamine stress echocardiography. *Circ J* 67:49-53
21. Spencer KT, Bednarz J, Mor-Avi V, DeCara J, Lang RM (2002) Automated endocardial border detection and evaluation of left ventricular function from contrast-enhanced images using modified acoustic quantification. *J Am Soc Echocardiogr* 15:777-781
22. Papademetris X, Sinusas AJ, Dione DP, Duncan JS (2001) Estimation of 3D left ventricular deformation from echocardiography. *Med Image Anal* 5:17-28
23. Mor-Avi V, Akselrod S, David D, Keselbrener L, Bitton Y (1993) Myocardial transit time of the echocardiographic contrast media. *Ultrasound Med Biol* 19:635-648
24. Jayaweera AR, Sklenar J, Kaul S (1994) Quantification of images obtained during myocardial contrast echocardiography. *Echocardiography* 11:385-396
25. Jayaweera AR, Edwards N, Glasheen WP, Villanueva FS, Abbott RD, Kaul S (1994) In vivo myocardial kinetics of air-filled albumin microbubbles during myocardial contrast echocardiography. Comparison with radiolabeled red blood cells. *Circ Res* 74:1157-1165
26. Wei K, Jayaweera AR, Firoozan S, Linka A, Skyba DM, Kaul S (1998) Quantification of myocardial blood flow with ultrasound-induced destruction of

- microbubbles administered as a constant venous infusion. *Circulation* 97:473-483
27. Janerot-Sjoberg B, von Schmalensee N, Schreckenberger A, Richter A, Brandt E, Kirkhorn J, Wilkenshoff U (2001) Influence of respiration on myocardial signal intensity. *Ultrasound Med Biol* 27:473-479
 28. Bekeredjian R, Hansen A, Filusch A, Dubart AE, Da Silva KG, Jr, Hardt SS, Korosoglou G, Kuecherer HF (2002) Cyclic variation of myocardial signal intensity in real-time myocardial perfusion imaging. *J Am Soc Echocardiogr* 15:1425-1431
 29. Masugata H, Peters B, Lafitte S, Monet G, Ohmori K, DeMaria AN (2001) Quantitative assessment of myocardial perfusion during graded coronary stenosis by real-time myocardial contrast echo refilling curves. *J Am Coll Cardiol* 37:262-269
 30. Masugata H, Lafitte S, Peters B, Strachan GM, DeMaria AN (2001) Comparison of real-time and intermittent triggered myocardial contrast echocardiography for quantification of coronary stenosis severity and transmural perfusion gradient. *Circulation* 104:1550-1556
 31. Linka AZ, Sklenar J, Wei K, Jayaweera AR, Skyba DM, Kaul S (1998) Assessment of transmural distribution of myocardial perfusion with contrast echocardiography. *Circulation* 98:1912-1920
 32. Lafitte S, Higashiyama A, Masugata H, Peters B, Strachan M, Kwan OL, DeMaria AN (2002) Contrast echocardiography can assess risk area and infarct size during coronary occlusion and reperfusion: experimental validation. *J Am Coll Cardiol* 39:1546-1554
 33. Di Bello V, Pedrinelli R, Giorgi D, Bertini A, Talini E, Mengozzi G, Palagi C, Nardi C, Dell'Omo G, Paterni M, Mariani M (2002) Coronary microcirculation in essential hypertension: a quantitative myocardial contrast echocardiographic approach. *Eur J Echocardiogr* 3:117-127
 34. Barron JL, Fleet DJ, Beauchemin SS (1994) Performance of optical flow techniques. *Int J Computer Vision* 12:43-77
 35. Hein IA, O'Brien WD (1993) Current time-domain methods for assessing tissue motion by analysis from reflected ultrasound echoes - A review. *IEEE Trans Ultrason, Ferroelec, Freq Contr* 40:84-102
 36. Mailloux GE, Langlois F, Simard PY, Bertrand M (1989) Restoration of the velocity field of the heart from two dimensional echocardiograms. *IEEE Trans Med Imag* 8:143-153
 37. Noble JA, Dawson D, Lindner J, Sklenar J, Kaul S (2002) Automated, nonrigid alignment of clinical myocardial contrast echocardiography image sequences: comparison with manual alignment. *Ultrasound Med Biol* 28:115-123
 38. Camarano G, Jones M, Freidlin RZ, Panza JA (2002) Quantitative assessment of left ventricular perfusion defects using real-time three-dimensional myocardial contrast echocardiography. *J Am Soc Echocardiogr* 15:206-213
 39. Yao J, De Castro S, Delabays A, Masani N, Udelson JE, Pandian NG (2001) Bulls-eye display and quantitation of myocardial perfusion defects using three-dimensional contrast echocardiography. *Echocardiography* 18:581-588

